

INDICATIONS FOR BRAIN CT SCAN IN PATIENTS WITH MINOR HEAD INJURY

Sadam Bin Ahsan^{*1}, Muhammad Uzair², Syed Muhammad Yousaf Farooq³, Shehrooz Ahmad Farrukh⁴, Fatima Abbas⁵, Zainab Haider⁶, Saira Tabassam⁷

^{*1,2,3,4,5,6,7}Department of Radiography & Imaging Technology of Green International University Lahore
The Emergency and Radiology Department of General Hospital Lahore.

¹sadambinahsan366@gmail.com, ²muzair477@gmail.com, ³fammabbas2@gmail.com, ⁴rafiqdrsaira@gmail.com, ⁵zainabhaider162@gmail.com, ⁶shahroz272458@gmail.com, ⁷yousafgelani@gmail.com

Corresponding Author: *

Sadam Bin Ahsan

DOI: <https://doi.org/10.5281/zenodo.16900660>

Received
09 May, 2025

Accepted
01 July, 2025

Published
15 August, 2025

ABSTRACT

Objectives

The aim of this study is to determine the frequency of utilization, yield for brain injury, incidence of missed injury, and variation in the use of computed tomography (CT) for ED patients with minor head injury.

Setting

The emergency and radiology department of General Hospital Lahore.

Methods

It was an observational study. A series of 400 consecutive patients who had been attended at two with minor head injury were prospectively enrolled in this study. In all cases clinical signs and symptoms were collected and a cranial computerized tomography (CT) scan was obtained. The relationship between the occurrence of clinical findings and appearance of intracranial posttraumatic lesions on cranial CT was analyzed by chi-square tests and statistic logistic regression methods, with 95% confidence intervals.

Results

400 patients, 51(12.8%) presented brain injuries on CT scan. All patients with abnormal CT scans had at least one of the following factors (risk factors): posttraumatic amnesia, loss of consciousness, posttraumatic seizure, headache, vomiting, focal neurological deficit, skull fracture, coagulopathy or antecedent of treatment with anticoagulants and patient age older than 60 years. No abnormal CT scans were found among patients without any of those risk factors on admission. Vomiting, skull fracture and age greater than 60 years were risk factors significantly correlated to an abnormal cranial CT after head injury. The presence of several risk factors in a patient increased the probability of posttraumatic lesion on CT scan.

Conclusions

Our study conducted which contain clinical risk factors that can be used as a guide to predict the probability of abnormal CT following minor head injury.

Keywords: CT (computed tomography), Brain injury, Head Trauma, Minor head injury.

INTRODUCTION

Head injuries are the most common types of trauma seen in emergency departments. A head injury is defined as an injury that damage to the brain and skull as a result of any trauma.¹ Head injury is the leading cause of death worldwide due to road traffic accidents. Due to head injury some of these patients die or suffer serious morbidity requiring months of hospitalization and Head injury is classified as having a “minimal” or “minor” head injury.²

Minor head injury is the most common type of head injury. A minor head injury is defined as an injury (like a bump or a cut) to the brain or skull. It's symptoms include headache, nausea, dizziness, vomiting and blurred vision.³ Minor head injury (MHI) represents the most common type of head injury assessed in emergency departments, reaching nearly the 85% of cases.⁴ Most of the patients with minor head injury can be discharged without sequelae after a period of observation, in a small proportion of patients, their neurologic condition deteriorates and requires neurosurgical intervention for intracranial hematoma.¹³ For diagnosis of minor head injury CT scan is used. The term “computed tomography,” or CT, refers to a computerized x-ray imaging procedure.⁵ Minor head injury symptoms such as headache, vomiting, loss of consciousness (LOC) or amnesia, and post-traumatic seizure are the common indication for the CT brain. Indications for CT scan might be different based on the main outcome measures, which could be the presence of any abnormal lesion. Patients with moderate or severe head injury, defined as a Glasgow Coma Scale (GCS) score of 12 or less are obvious candidates for urgent CT.⁶

It has become apparent that excess mortality and delayed diagnosis could be reduced in head injury by early use of computed tomography (CT). At the same time, plain skull radiography has been discouraged because of its very low yield. With the use of CT scan in minor head injury diagnosis can be made on time.⁷ The brain computed tomography (CT) scan is a good

investigation to rule out the minor head injury.³ In recent years, the use of CT for minor head injury has become increasingly common.⁸ The increased use of CT adds substantially to health care costs and exposes a large number of patients each year to the potentially harmful effects of ionizing radiation.⁹ Therefore, there is a little controversy about use of CT scan for minor head injury patients. Therefore, Clinical features can also be used to identify which patients with minor brain injury need CT scanning.¹⁰

The use of computed tomography (CT) in the emergency department is important in the early diagnosis of intracranial damage and to make an accurate decision for treatment in combination with clinical findings.¹¹ The aim of this study is to determine the frequency of utilization, yield for brain injury, incidence of missed injury, and variation in the use of computed tomography (CT) for ED patients with minor head injury.¹²

Methods:

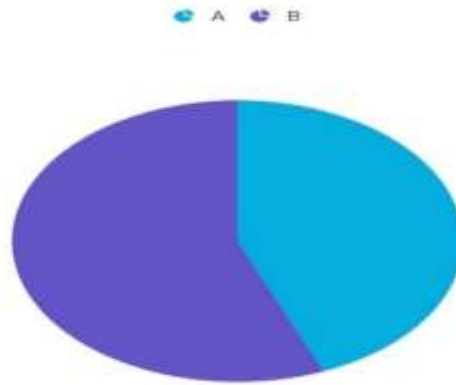
This prospective cohort study included all patients with MHI (GCS score of 15), who were older than 6 years old and had been assessed in the emergency department of General hospital Lahore between June 2024 and June 2025. Initially a literature review of the risk factors associated with the presence of intracranial lesions on cranial CT of MHI patients was carried out. Ten clinical signs and symptoms or previous medical conditions were selected as risk factors to be tested. Signs include vomiting, nausea, headache and Vertigo etc.

Results:

All patients were examined and scanned in order to find intracranial injuries. 400 were included both male and female. 175 were female and 225 were male. The most common cause of head injury was motor vehicle accident (88.2%). Fall (7.1%) and assault (3%) were the next, respectively.

Gender:

Gender	Frequency	Percentages
Female	175	43.8
Male	225	56.3
Total	400	100



Indications:

TABLE NO.1

Clinical Findings	Frequency	Percentages
Headache	339	84.8
Vomiting	125	31.3
Vertigo	135	33.8
Seizures	22	68
Short term memory deficit	29	7.3
Alcohol intoxication	19	4.1
Loss of consciousness	321	80.3

The clinical findings of the study shows that 339 individuals (84.8%) identified headaches as their most common complaint. Vertigo (33.8%), vomiting (31.3%), and loss of consciousness (80.3%) were other

common symptoms. 22 patients 68.0% of the total, had seizures. Furthermore, alcohol intoxication was observed in 19 cases (4.1%) and short-term memory impairments were observed in 29 patients (7.3%).

TABLE NO.2

Radiological Findings	Frequency	Percentages
Infarction	36	9.0
Hemorrhage	54	13.5
Contusion	65	16.3
Brain herniation	16	4.5
Edema	35	8.8
Midline shift	30	7.5
Hydrocephalus	19	4.8
Hematoma	67	16.8
Trauma above clavicle	56	14.0
Fracture	51	12.8

The radiological studies shows that the most frequent finding, Hematoma, was seen in 16.8% of cases, closely followed by contuse on in 16.3% of instances. Hemorrhage occurred in 13.5% of instances, and 14% of patients had trauma above the clavicle. In 9% of cases, infarction was discovered, and in 12.8% of cases, fractures were observed. Edema (8.8%), midline shift (7.5%), and hydrocephalus (4.8%) were among the

other conditions. Brain herniation was the least frequent finding, occurring in 4.5% of the patients.

Discussion

The evaluation of patients with minor head injury (MHI) continues to pose a diagnostic challenge, particularly in determining the appropriate use of brain computed tomography (CT) scanning. While

CT is the gold standard for detecting intracranial injuries, its widespread use in patients with minor trauma has raised concerns regarding overutilization, radiation exposure, and healthcare costs. Specific clinical findings such as loss of consciousness, amnesia, vomiting, seizures, focal neurological deficits, signs of skull fracture, and a Glasgow Coma Scale (GCS) score less than 15 two hours post-injury. Our findings are consistent with previous literature in highlighting these features as critical predictors of intracranial pathology in minor head trauma.

Radiological abnormalities such as hematoma (16.8%) and contusion (16.3%) were significantly associated with clinical indicators such as short-term memory loss (7.3%), headache (84.8%), vomiting (31.3%), and loss of consciousness (80.3%) in our study of 400 patients with head injuries. These results are in alignment with previous studies by Stiell et al. (2001) and Smits et al. (2007), which emphasize the importance of symptoms like LOC, vomiting, severe headache, amnesia, and indications of skull fracture as significant predictors of intracranial injury. They also support the use of CT imaging in patients with mild head injury (MHI). The importance of clinical evaluation in guiding imaging decisions for identifying severe mental pathology is highlighted by both studies.²⁴

In our study of 400 head injury patients, clinical indicators such as headache (84.8%), loss of consciousness (80.3%), vomiting (31.3%), and Intoxication (4.1%) and vomiting (31.3%) have been frequently reported, which is consistent with the high-risk features listed by the Canadian CT Head Rule (CCHR). The application of CCHR, which prioritizes harmful mechanisms, LOC, and amnesia in assessing CT need, is further supported by the prevalence of motor vehicle accidents (88.2%) as a mechanism of injury. Our results are more consistent with the increased specificity and selective use of imaging in CCHR than with the New Orleans Criteria (NOC), which incorporates broader markers. Radiological results, such as hematoma (16.8%) and contusion (16.3%), support the value of tailored CT use based on clinical risk factors. This is in line with Smits et al. (2005), who showed that CCHR effectively lowers the number of unnecessary CT scans.²⁵

A study by Haydel et al. (2000) Computed tomography (CT) is widely used as a screening test in patients with minor head injury, although the results are often normal. They performed a study to develop and validate a set of clinical criteria that could be used to identify patients with minor head injury who do not need to undergo CT. They established a clinical

decision to rule identifying LOC, headache, vomiting, and signs of skull fracture as high-yield predictors for intracranial injury. Our findings support the use of these criteria in guiding imaging decisions in emergency setting.⁷

Although routine imaging is discouraged in low-risk mild head injury cases, Mower et al. (2005) highlighted the ongoing issue of over triage in ERs, where CT scans are often ordered in advance because of patient expectations, medicolegal concerns, and diagnostic uncertainty. Their findings demonstrate the need for stricter adherence to clinical decision standards to minimize unnecessary CT use. Radiological results of hematoma (16.8%) and contusion (16.3%) were significant in comparison to vomiting (31.3%) and loss of consciousness (80.3%). Although our findings promote customized CT use based on clinical indications, overtriage may still happen even when evidence-based recommendations like the Canadian CT Head Rule are applicable.²³

Our analysis supports a more judicious application of CT scanning, emphasizing the value of validated clinical decision rules. Incorporating such guidelines in routine practice not only improves patient safety by minimizing radiation exposure but also optimizes resource utilization in emergency departments.

Conclusions

Our study conducted which contain clinical risk factors that can be used as a guide to predict the probability of abnormal CT following minor head injury.

REFERENCES

- Stiell, I. G., Lesiuk, H., Wells, G. A., Coyle, D., McKnight, R. D., Brison, R., ... & Laupacis, A. (2001). Canadian CT head rule study for patients with minor head injury: methodology for phase II (validation and economic analysis). *Annals of emergency medicine*, 38(3), 317-322.
- Saboori, M., Ahmadi, J., & Farajzadegan, Z. (2007). Indications for brain CT scan in patients with minor head injury. *Clinical neurology and neurosurgery*, 109(5), 399-405.3.
- Snoey, E. R., & Levitt, M. A. (1994). Delayed diagnosis of subdural hematoma following normal computed tomography scan. *Annals of emergency medicine*, 23(5), 1127-1131.

- Pandor, A., Goodacre, S., Harnan, S., Holmes, M., Pickering, A., Fitzgerald, P., ... & Stevenson, M. (2011). Diagnostic management strategies for adults and children with minor head injury: a systematic review and an economic evaluation. *Health technology assessment (Winchester, England)*, 15(27), 1.
- Harnan, S. E., Pickering, A., Pandor, A., & Goodacre, S. W. (2011). Clinical decision rules for adults with minor head injury: a systematic review. *Journal of Trauma and Acute Care Surgery*, 71(1), 245-251.
- Erlichman, D. B., Blumfield, E., Rajpathak, S., & Weiss, A. (2010). Association between linear skull fractures and intracranial hemorrhage in children with minor head trauma. *Pediatric radiology*, 40, 1375-1379.
- Haydel, M. J., Preston, C. A., Mills, T. J., Luber, S., Blaudeau, E., & DeBlieux, P. M. (2000). Indications for computed tomography in patients with minor head injury. *New England Journal of Medicine*, 343(2), 100-105.
- Miller, E. C., Derlet, R. W., & Kinser, D. (1996). Minor head trauma: Is computed tomography always necessary?. *Annals of emergency medicine*, 27(3), 290-294.
- Vicario, S., Danzl, D., & Thomas, D. M. (1982). Emergency presentation of subdural hematoma: A review of 85 cases diagnosed by computerized tomography. *Annals of Emergency Medicine*, 11(9), 475-477.
- Harnan, S. E., Pickering, A., Pandor, A., & Goodacre, S. W. (2011). Clinical decision rules for adults with minor head injury: a systematic review. *Journal of Trauma and Acute Care Surgery*, 71(1), 245-251.
- Iverson, G. L., Lange, R. T., Wäljas, M., Liimatainen, S., Dastidar, P., Hartikainen, K. M., ... & Öhman, J. (2012). Outcome from complicated versus uncomplicated mild traumatic brain injury. *Rehabilitation research and practice*, 2012(1), 415740.
- Maas, A. I., Menon, D. K., Manley, G. T., Abrams, M., Åkerlund, C., Andelic, N., ... & Zemek, R. (2022). Traumatic brain injury: progress and challenges in prevention, clinical care, and research. *The Lancet Neurology*, 21(11), 1004-1060.
- Brenner, D. J., & Hall, E. J. (2007). Computed tomography—an increasing source of radiation exposure. *New England journal of medicine*, 357(22), 2277-2284.
- Levin, H. S., & Diaz-Arrastia, R. R. (2015). Diagnosis, prognosis, and clinical management of mild traumatic brain injury. *The Lancet Neurology*, 14(5), 506-517.
- Gronwall, D. (1991). Minor head injury. *Neuropsychology*, 5(4), 253.
- Osmond, M. H., Klassen, T. P., Wells, G. A., Correll, R., Jarvis, A., Joubert, G., ... & Stiell, I. G. (2010). CATCH: a clinical decision rule for the use of computed tomography in children with minor head injury. *Cmaj*, 182(4), 341-348.
- Mannix, R., Meehan, W. P., Monuteaux, M. C., & Bachur, R. G. (2012). Computed tomography for minor head injury: variation and trends in major United States pediatric emergency departments. *The Journal of pediatrics*, 160(1), 136-139.
- Ono, K., Wada, K., Takahara, T., & Shirotani, T. (2007). Indications for computed tomography in patients with mild head injury. *Neurologia medico-chirurgica*, 47(7), 291-298.
- Sharif-Alhoseini, M., Khodadadi, H., Chardoli, M., & Rahimi-Movaghar, V. (2011). Indications for brain computed tomography scan after minor head injury. *Journal of emergencies, trauma, and shock*, 4(4), 472-476.
- Shackford, S. R., Wald, S. L., Ross, S. E., Cogbill, T. H., Hoyt, D. B., Morris, J. A., ... & Sugerman, H. J. (1992). The clinical utility of Computed tomographic scanning and neurologic examination in the management of patients with minor head injuries. *Journal of Trauma and Acute Care Surgery*, 33(3), 385-394.
- Leaman, A. M. "The NICE guidelines for the management of head injury: the view from a district hospital." *Emergency Medicine Journal* 21.4 (2004): 400-400.
- Haydel, M. J., Preston, C. A., Mills, T. J., Luber, S., Blaudeau, E., & DeBlieux, P. M. (2000). Indications for computed tomography in patients with minor head injury. *New England Journal of Medicine*, 343(2), 100-105. <https://doi.org/10.1056/NEJM200007133430204>
- Mower, W. R., Hoffman, J. R., Herbert, M., Wolfson, A. B., Pollack, C. V., & Zucker, M. I. (2005). Developing a decision instrument to guide computed tomographic imaging of blunt head injury patients. *Journal of Trauma*, 59(4), 954-959. <https://doi.org/10.1097/01.ta.0000187813.79047.6f>

National Institute for Health and Care Excellence (NICE). (2014). Head injury: assessment and early management (Clinical guideline CG176). Retrieved from <https://www.nice.org.uk/guidance/cg176>
Smits, M., Dippel, D. W., de Haan, G. G., Dekker, H. M., Vos, P. E., Kool, D. R., & Hunink,

M. G. (2005). External validation of the Canadian CT Head Rule and the New Orleans Criteria for CT scanning in patients with minor head injury. *JAMA*, 294(12), 1519-1525. <https://doi.org/10.1001/jama.294.12.1519>

