

CLINICAL OCCURRENCE OF ORAL POTENTIALLY MALIGNANT DISORDERS IN HEPATITIS C POSITIVE PATIENTS

Dr. Fatima Tuz Zahara^{*1}, Dr. Hafiz Muhammad Majid Jehangir², Dr. Mariyah Javed³,
Dr. Hassan Tariq Bhatti⁴, Dr. Khurram Shehzad⁵

^{*1}M. Phil Oral Pathology, Scholar at Superior University Lahore

²Professor of Oral Pathology Azra Naheed Dental College Superior University

³Associate Professor, Oral Pathology Rahbar College of Dentistry

⁴Oral Maxillofacial Surgeon DHQ hospital/Khawaja Safdar Medical College Sialkot

⁵Associate Professor of Histopathology Khawaja Safdar Medical College Sialkot

¹zahrafatima440@gmail.com, ²majid.jehangir@superior.edu.pk, ³mariyah.javed@hotmail.com

²ORCID ID 0009-0003-3059-3257

Corresponding Author: *

Dr. Fatima Tuz Zahara

DOI: <https://doi.org/10.5281/zenodo.18277773>

Received
16 November 2025

Accepted
29 December 2025

Published
16 January 2026

ABSTRACT

Background: Hepatitis C is spreading in Pakistan with alarming increase in number. It can cause hepatocellular carcinoma and according to different studies it has some relation with oral potentially malignant disorders and oral cancer. In Pakistan oral potentially malignant disorders also increasing in number.

Materials and methods: It was observational cross-sectional study. Duration of the study was six months. 100 patients with hepatitis C positive patients were included in study group. 100 patients had no HCV infection were included in healthy control group. Oral examination was done clinically to check presence and type of oral potentially malignant disorders in both groups.

Results: only four patients had oral potentially malignant disorders in non-HCV control group. Twelve patients had oral potentially malignant disorders in HCV positive study group. Six percent of patients had oral lichen planus, three percent of patients had erythroplakia and two percent of patients had leukoplakia and only one percent of patients had oral submucous fibrosis.

Conclusion: oral potentially malignant disorders are more in hepatitis C patients. Early diagnosis of these disorders prevents their conversion into squamous cell carcinoma in hepatitis C infection.

Keywords: Hepatitis C, oral premalignant lesions, oral premalignant disorders, Ora lichen planus, oral leukoplakia, oral erythroplakia

INTRODUCTION

Hepatitis C virus infection is spreading in Pakistan with an alarming pace. Approximately 4.3 percent population in Pakistan is effected by hepatitis C infection. (1) Hepatitis C effect on almost 58 million of the world's population. (2) Hepatitis C is spreading by direct contact to

infected blood. Infected needles, surgical instruments used by doctors and dentists. Hepatitis C also spread by barbers, beauty salons and tattoo makers which used sharp instruments. (3) Hepatitis C virus infection mostly causes chronic hepatitis and hepatocellular carcinoma.

It also shows manifestation other than hepatic manifestations. (4)

It does not limit to effect upon liver only, but it has many other manifestations including oral manifestations. Hepatitis C infection usually associated with oral manifestations such as Sjogren's syndrome, angular cheilitis, reduction in saliva, taste changes and oral lichen planus. (5) Oral lichen planus one the oral potentially malignant disorder which have significant association with hepatitis C. (6) Oral potentially malignant disorders including both premalignant lesions and premalignant disorder. Most commonly oral disorders are leukoplakia, erythroplakia, oral lichen planus, oral submucous fibrosis etc. (7) Most of the studies have researched about either HCV alone or oral premalignant lesions alone. Only few studies had researched on association with oral lichen planus and hepatitis C but not with other potentially malignant oral disorders.

Materials and methods

It was observational cross-sectional study. Target population was patients who visited in main district hospital Sialkot. Sample collection method was convenient sampling technique.

Two groups of patients were made. Study groups had 100 patients who had HCV infection.

Control group had 100 patients who were tested negative for HCV infection.

Inclusion criteria:

- Patients who had HCV infection whether treated or not treated.
- Patients who give consent.
- Patients who were above 18 years old.

Exclusion criteria

- Smokers and Pan chalia users.
- Patients who had history of oral cancer.
- Patients who had immunocompromised such as patients who had radiotherapy, renal or liver transplant and HIV patients
- Pregnant patients

Demographic, medical and history about lesion were taken by patients in both groups.

Thorough clinical oral examination of patients done in both groups.

Results

Forty percent of patients were male, and sixty percent of the patients were female in study group. Most of the patients belonged to 35-60 age group. Mostly patients had low socioeconomic class, and oral hygiene was moderate to poor in both study groups.

Table 1. Demographic Characteristics of study and control groups

Variable	Study group n/	Control group n/
Gender		
Male	40/	45/
Female	60/	55/
Age group		
18-35	10/	20/
36-50	65/	60/
51-70	35/	20/
Socio economic status		
Moderate	10/	15/
Low	90/	85/

Twelve percent of the patients had Oral potentially malignant disorders in study group while six percent of the patients had oral potentially malignant disorders in control group. There were six percent of the patients had oral

lichen planus (one percent erosive lichen planus and five percent reticular lichen planus). Three percent patients had erythroplakia and two percents had oral leukoplakia and only percent of patients had oral submucous fibrosis. In control

group three percent of the patients had leukoplakia and one percent of the patients had oral erythroplakia.

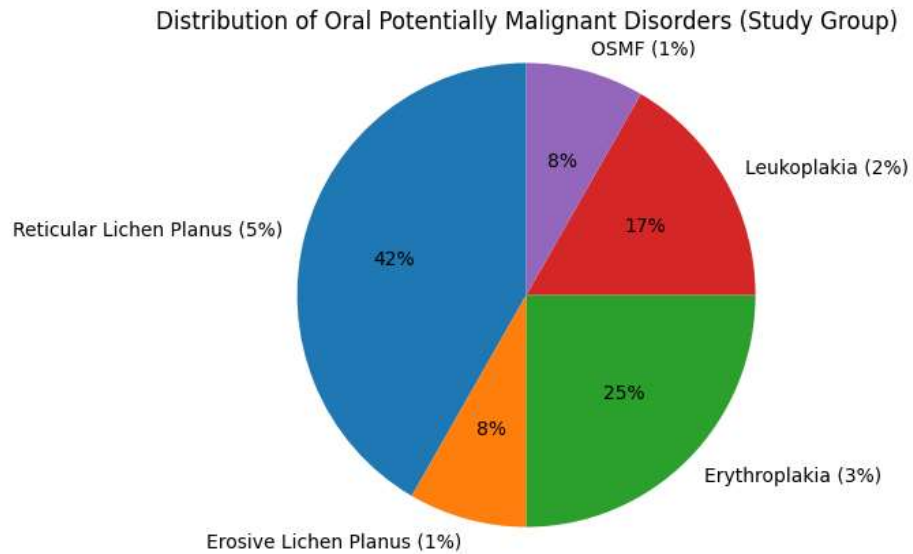


Figure: Pie chart showing distribution of oral potentially malignant disorders in study group (hepatitis C positive patients)

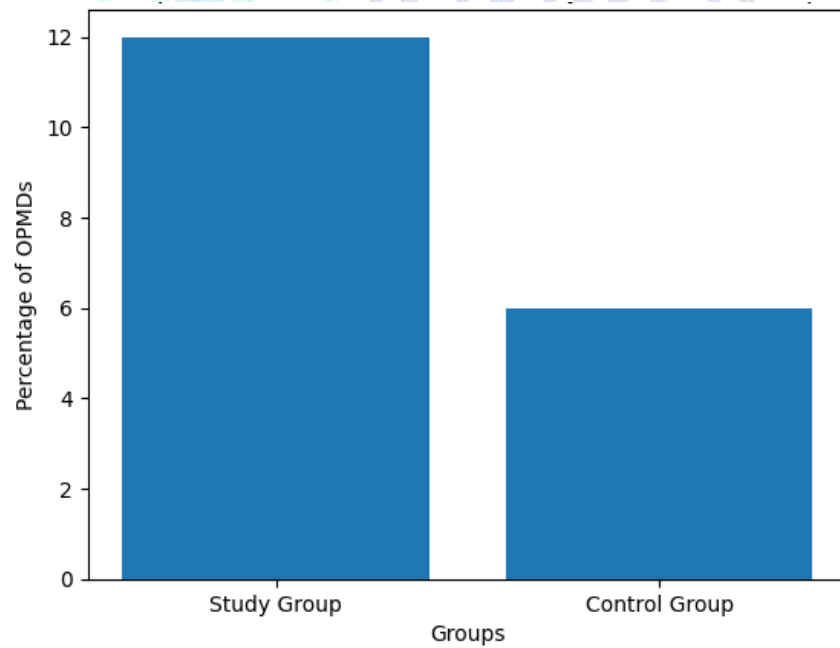


Figure 2: Bar graph showing comparison of percentage of oral potentially malignant disorder in study and control group

Table.2: frequency of oral potentially malignant disorder in Study and control group

Most of the patients which had increased viral load had complaint of bitter taste, coated tongue and reduced saliva. Most of the lesions were present at buccal mucosa and lateral and dorsum side of the tongue.

Oral potentially malignant disorder	Study group	Control group
Oral lichen planus	6/	0/
-Reticular type	5/	0/
-erosive type	1/	0/
Oral leukoplakia	2/	3/
Oral erythroplakia	3/	1/
Oral submucous fibrosis	1/	0/
Total	12/	4/

Table 3: Associations of viral load with oral symptoms in study group

Oral symptoms	Increased viral load
Bitter taste	Present
Coated tongue	Present
Reduced saliva	Present

Chi-square test was used to perform comparative analysis between two groups. Chi-square test analysis showed that higher frequency of oral potentially malignant disorders in hepatitis C patients which had increased viral load. ($X^2=4.02$, $df=1$ and $p=0.045$). P value was less than 0.05 which is significant. This analysis suggested that positive relation between hepatitis C positive patients and oral potentially malignant disorders

Discussion

In our study prevalence of oral potentially malignant disorders was twelve percent in Hepatitis C positive patients. Oral lichen planus was diagnosed in six percent of the hepatitis C patients. In one study in Egypt, they found frequency of xerostomia (40%), altered taste (24%) and oral lichen planus (20%) higher in hepatitis C positive patients.(8) In a systemic review and meta-analysis conducted in Saudi Arabia different studies prevalence of oral lichen planus was 0.3-11 percent but, in their study, they did not found viral load of the patients.(9) A study in Pakistan showed 10 percent of the patients showed oral lichen planus. They also checked their ELIZA test of HCV and liver function tests. In our study we checked PCR quantitative test for HCV, but we did not checked

liver function tests of every patient. According to their study oral lichen planus had positive association with hepatitis C. (10)

In a study researchers had found 4.4 percent oral potentially malignant disorders in hepatitis C positive patients. (11) This was the first study in which researchers wanted to found association of oral potentially malignant disorders in HCV positive patients. This study aligns with our study in this aspect, but this study conducted by help of government and had large number of patients Female ratio of having oral lichen planus is more than males. In another study 68/ of the patients were females while 31 percent were males which had oral lichen planus this finding aligns with our finding.(12) In an systemic review and meta-analysis they found oral lichen planus were present in more female than in males.(13) In our study patient usually complaint about dryness in mouth and bitter taste which was similar to many studies including a study in Poland. (14) Dryness of the oral cavity is due to the reduced saliva because HCV have effect on salivary glands. (15) Coated tongue was also found in majority of the patients who had Hepatitis C infection. In many studies they found this finding which was due to change in microbiota and increased viral load. (16)

Limitations and future recommendations

Relatively small sample size, only clinical diagnosis and no histological diagnosis were limitations in this study. In future large sample size, histopathological correlation and studies with follow-up of oral potentially malignant disorders are recommended

Conclusions

Oral potentially malignant disorders especially oral lichen planus has significant association. Oral examination of every HCV positive patient should be done whether they complaint about any discomfort or not. This will ensure early detection and treatment of oral potentially malignant disorders.

References

- Mooneyhan E, Qureshi H, Mahmood H, Tariq M, Maqbool NA, Anwar M, et al. Hepatitis C prevalence and elimination planning in Pakistan, a bottom-up approach accounting for provincial variation. *Journal of Viral Hepatitis*. 2023 Apr;30(4):345–54.
- Fleurence RL, Alter HJ, Collins FS, Ward JW. Global Elimination of Hepatitis C Virus. *Annual Review of Medicine*. 2025 Jan 27;76(1):29–41.
- Sheikh AN, Siddiquee B, Chahande J. Hepatitis B and C infection among dentists - Risk, prevention, and management. *JADPR*. 2022 June 30;1:31–6.
- Alawya B, Constantinou C. Hepatocellular Carcinoma: a Narrative Review on Current Knowledge and Future Prospects. *Curr Treat Options in Oncol*. 2023 July;24(7):711–24.
- Åberg F, Helenius-Hietala J. Oral Health and Liver Disease: Bidirectional Associations—A Narrative Review. *Dentistry Journal*. 2022 Jan 21;10(2):16.
- González-Moles Má, De Porrás-Carrique T, Ramos-García P. Association of oral lichen planus with hepatic disorders and hepatocellular carcinoma: systematic review and meta-analysis. *Med Oral*. 2023;e229–37.
- Tarakji B. Dentists' Perception of Oral Potentially Malignant Disorders. *International Dental Journal*. 2022 June;72(3):414–9.
- Ismail R, Elansary A, Ezzatt O, Hamed M, Gamil Y. Hepatitis C associated oral lesions: A hospital-based retrospective case control study in Egypt. *J Int Oral Health*. 2023;15(1):52.
- Understanding Oral Lichen Planus and Its Malignant Potential in the Saudi Arabian Population: A Systematic Review. *Oral Health and Preventive Dentistry*. 2025 Jan 8;23(1):691–9.
- Shahzadi N, Altaf F, Raffad Dr, Anjum R, Saeed W, Butt G. Association of hepatitis C virus with various forms of lichen planus. *J Pak Assoc Dermatol*. 2019 Sept 1;29(1):110–3.
- Jumparway D, Hsu CY, Yen AMF, Lin TY, Warnakulasuriya S, Chen THH, et al. Hepatitis C Virus Infection Associated with Oral Potentially Malignant Disorder, Oral Cancer, and Liver Diseases: A Community-Based Cross-Sectional Study. *Cancers*. 2025 Nov 18;17(22):3695.
- Mostafa B, Ahmed E. Prevalence of oral lichen planus among a sample of the Egyptian population. *J Clin Exp Dent*. 2015;e7–12.
- Li C, Tang X, Zheng X, Ge S, Wen H, Lin X, et al. Global Prevalence and Incidence Estimates of Oral Lichen Planus: A Systematic Review and Meta-analysis. *JAMA Dermatol*. 2020 Feb 1;156(2):172.
- Kędziora-Ciechańska A, Ciechański K, Chałas R. Impaired Gustation in Liver Diseases: A Comprehensive Narrative Literature Review. *Acta Stomatol Croat*. 2025 Dec 15;59(4):426–39.
- Maldonado JO, Beach ME, Wang Y, Perez P, Yin H, Pelayo E, et al. HCV Infection Alters Salivary Gland Histology and Saliva Composition. *J Dent Res*. 2022 May;101(5):534–41.
- AlBeshri S. Perspectives on tongue coating: etiology, clinical management, and associated diseases – a narrative review. *Saudi Dent J*. 2025 Oct;37(7–9):41.